

Spontaneous Septic Embolic Encephalitis and Endophthalmitis in a Recovering Polytrauma Patient: A Case Report

Hashim Mohammad ^{1,*}, Ankit Agarwal ¹, Sonu Sama ¹, Sana Kausar ²

¹ Department of Anaesthesiology and Critical Care, All India Institute of Medical Sciences, Rishikesh, Uttarakhand 249203, India; drankit80@gmail.com (A.A.); sonusama9287@gmail.com (S.S.)

² Department of Anaesthesiology and Critical Care, Jawaharlal Nehru Medical College, Aligarh, Uttar Pradesh 202002, India; mesanain@gmail.com

* Corresponding author: buxhashim@gmail.com

Submitted: 21 July 2020, accepted: 19 August 2020, published: 14 September 2020

Abstract: In polytrauma cases with thoracic injury and long-term chest tube drain, there is a risk of pulmonary arteriovenous fistula formation, which mostly remains undiagnosed. The pulmonary arteriovenous fistulas lead to the right to left shunt and could be a potential source of systemic septic embolism. Here, we describe a recovering polytrauma patient, who spontaneously developed septic embolic encephalitis and endogenous endophthalmitis, with no evident source of septic systemic embolism. We suspect the pulmonary arteriovenous fistulas due to thoracic injury or chest tube drain could be the possible source of septic systemic embolism, which needs to be evaluated in such cases after excluding common causes.

Keywords: pulmonary arteriovenous fistulas; chest tube drain; septic embolism

How to cite: Mohammad, H.; Agarwal, A.; Sama, S.; Kausar, S. Spontaneous Septic Embolic Encephalitis and Endophthalmitis in a Recovering Polytrauma Patient: A Case Report *Cent. Eur. Ann. Clin. Res.* **2020**, *2*(1), 2; doi:[10.35995/ceacr2010002](https://doi.org/10.35995/ceacr2010002).

© 2020 Copyright by the authors. Licensed as an open access article using a CC BY 4.0 license.



Introduction

Septic embolism is a critical but often under-reported class of infectious complications. It can be associated with various early and late sequelae. The common causes are bacterial endocarditis, septic thrombophlebitis, central venous catheter, and periodontal infection. However, other intravascular devices can also act as a source of infection and embolism [1]. Immediate complications are the vascular occlusion of the downstream vasculature like cerebral, myocardial, or bowel infarction [2]. Abscesses and mycotic aneurysms are most common among the late complications [3].

Here we want to highlight pulmonary arteriovenous fistulas as a possible source of spontaneous septic embolism in the patient with thoracic injury and chest tube drain.

Case Report

A 23-year-old male patient with a history of road traffic accident presented to the emergency department with multiple fractures, right-side pneumothorax, and shock. After initial resuscitation, a chest tube drain was placed. In view of increasing respiratory distress, the patient was intubated and then shifted to ICU for further management. Empirical antibiotics (ceftriaxone and amikacin) were started and a central venous catheter was secured for vasopressor support. He was tracheostomized on day five of presentation, in view of poor lung conditions and prolonged ventilation. On blood culture, Pan-drug resistant *Klebsiella pneumonia* was reported which showed sensitivity to colistin, but differential time to positivity was less than 120 min and the string test was negative, for which a central venous catheter was changed and injection Meropenem and Colistin were started.

The patient was gradually improved and on day eight of presentation; he was weaned off from the ventilator with a GCS (Glasgow coma scale) of E4VTM6. On the next day, he spontaneously developed right eye redness and pupil haziness for which fundoscopy was done and, in view of suspicion of endogenous endophthalmitis, an intravitreal injection of colistin and vancomycin were started. On the same day, his GCS also started deteriorating for which brain magnetic resonance imaging (MRI) was done, showing multiple emboli to the brain (see Figure 1).

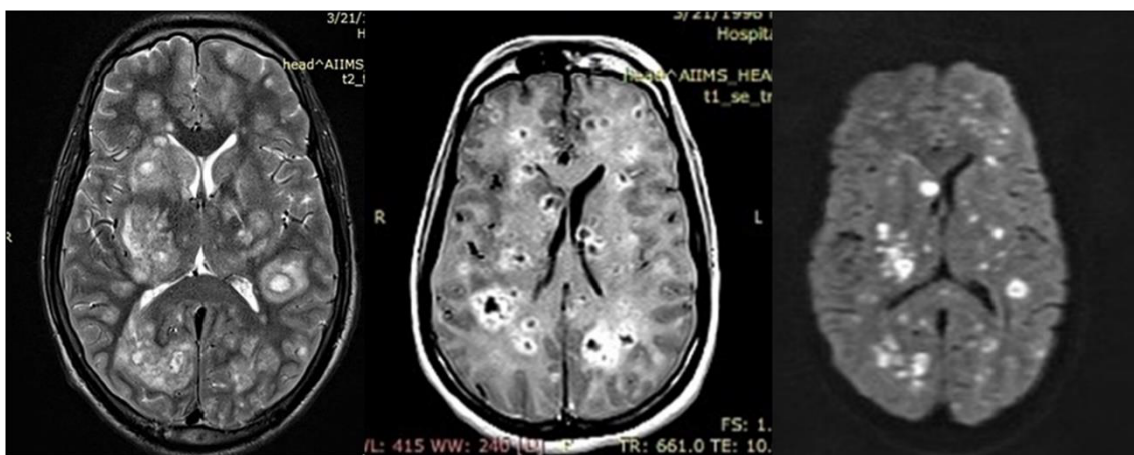


Figure 1. Magnetic resonance imaging (MRI) T2, T1 and diffusion restriction sequence showing multiple infarcts (septic emboli).

An abdominal computed tomography (CT) scan was also done, which did not show evidence of any solid organ abscess (see Figure 2).

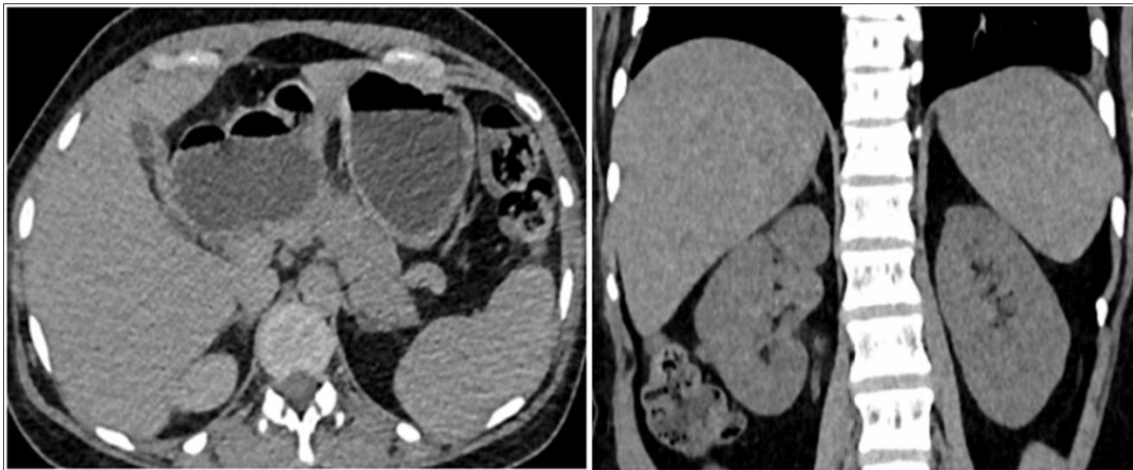


Figure 2. Axial and coronal view of computed tomography (CT) scan abdomen (normal).

Infective endocarditis and the presence of shunt were ruled out by transesophageal echocardiography (see Figure 3).

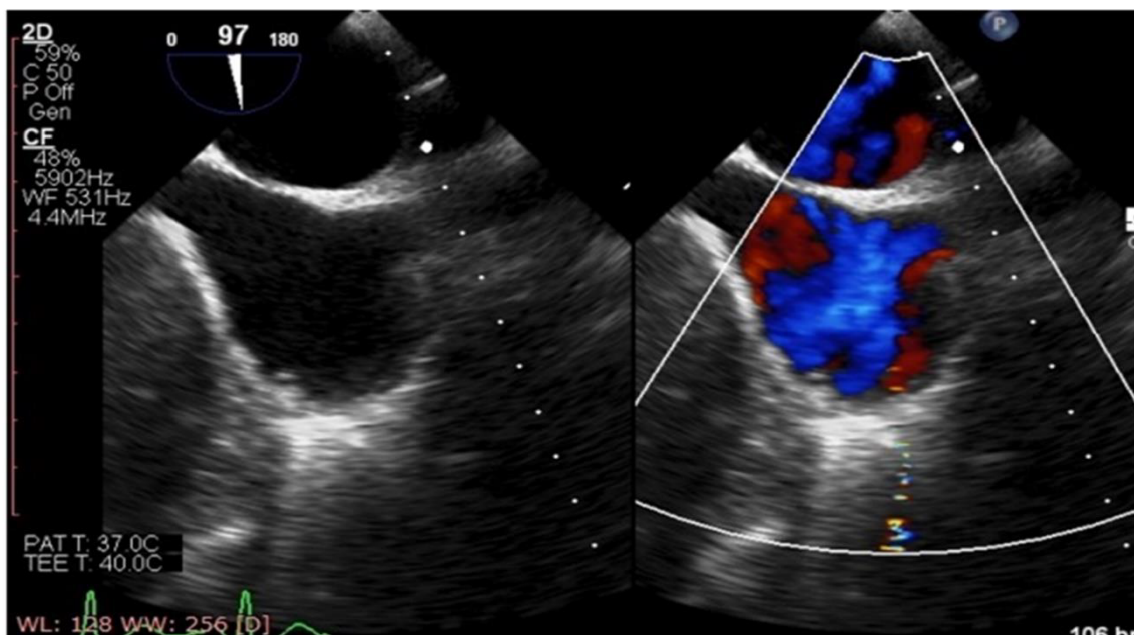


Figure 3. Transesophageal echocardiography showing no vegetation or shunt.

The septic shock gradually worsened and the patient died on day twelve of presentation.

Discussion

Most of the cases of septic embolic encephalitis and endogenous endophthalmitis are due to infective endocarditis or cardiac shunt and remaining others are because of indwelling catheters. However, our patient had normal transesophageal echocardiography and there was no evidence of indwelling catheters as a source of septic embolism. Another possibility could be a klebsiella invasive syndrome, but there was no evidence of solid organ abscess on the CT scan and the string test for the hyper-viscous colony (a marker of hyper-virulence) was also negative [4].

The possible explanation of the presented case is the presence of a chest tube drain that could have led to systemic embolization by pulmonary arteriovenous fistulas. The pulmonary

arteriovenous fistulas occur when pulmonary arteries directly drain into pulmonary veins, bypassing the capillary circulation and form right to left shunt, and can be the potential cause of systemic embolism. The trauma to the thoracic wall or pulmonary vessels by penetrating injury, including chest tube drainage, can lead to systemic or pulmonary arteriovenous fistulas, which can be diagnosed by selective angiography or contrast-enhanced magnetic resonance imaging. The therapeutic angiographic embolization or surgical excisions of the fistulas are the treatment modalities [5,6].

Conclusion

Systemic septic embolism is a serious complication with a high fatality rate. Sometimes the source of systemic embolism goes undetermined. In polytrauma cases with thoracic injuries and chest tube drain, we suspect a much higher incidence of pulmonary arteriovenous fistulas as a potential source of systemic embolism than reported and should be investigated after the exclusion of common causes.

Author Contributions: Conceptualization, Hashim Mohammad, Ankit Agarwal, Sonu Sama and Sana Kausar; Validation, Hashim Mohammad, Ankit Agarwal, Sonu Sama and Sana Kausar; Formal Analysis, Hashim Mohammad and Ankit Agarwal; Investigation, Hashim Mohammad and Sana Kausar; Resources, Hashim Mohammad and Sonu Sama; Data Curation, Hashim Mohammad and Ankit Agarwal; Writing—Original Draft Preparation, Hashim Mohammad; Writing—Review and Editing, Hashim Mohammad, Ankit Agarwal, Sonu Sama and Sana Kausar; Visualization, Hashim Mohammad and Ankit agarwal; Supervision, Hashim Mohammad; Project Administration, Hashim Mohammad and Ankit agarwal.

Funding: This research received no external funding.

Acknowledgments: The Author(s) like to acknowledge Mohammad Qasim (IIT, IIM) for his technical support and grammar editing.

Conflicts of Interest: The authors declare no conflict of interest.

References

1. Fidan, F.; Acar, M.; Unlu, M.; Cetinkaya, Z.; Haktanir, A.; Sezer, M. Septic pulmonary emboli following infection of peripheral intravenous cannula. *Eur. J. Gen. Med.* **2006**, *3*, 132–135. [[CrossRef](#)]
2. Caraballo, V. Fatal myocardial infarction resulting from coronary artery septic embolism after abortion: Unusual cause and complication of endocarditis. *Ann. Emerg. Med.* **1997**, *29*, 175–177. [[CrossRef](#)]
3. Cassada, D.C.; Stevens, S.L.; Schuchmann, G.S.; Freeman, M.B.; Goldman, M.H. Mesenteric pseudoaneurysm resulting from septic embolism. *Ann. Vasc. Surg.* **1998**, *12*, 597–600. [[CrossRef](#)] [[PubMed](#)]
4. Siu, L.K.; Yeh, K.M.; Lin, J.C.; Fung, C.P.; Chang, F.Y. Klebsiella pneumoniae liver abscess: A new invasive syndrome. *Lancet Infect. Dis.* **2012**, *12*, 881–887. [[CrossRef](#)]
5. Coulter, T.D.; Maurer, J.R.; Miller, M.T.; Mehta, A.C. Chest wall arteriovenous fistula: An unusual complication after chest tube placement. *Ann. Thorac. Surg.* **1999**, *67*, 849–850. [[CrossRef](#)]
6. Gilbert, T.B.; McGrath, B.J.; Soberman, M. Chest tubes: Indications, placement, management, and complications. *J. Intensive Care Med.* **1993**, *8*, 73–86. [[CrossRef](#)] [[PubMed](#)]