

## Ischemic Stroke Secondary to Cerebral Venous Thrombosis: A Case Report

Doina Georgescu <sup>1,\*</sup>, Daniela Reisz <sup>2</sup>, Izabella Petre <sup>3</sup>, Ioana Ionita <sup>4</sup>

<sup>1</sup> Department of Internal Medicine, "V. Babes" University of Medicine and Pharmacy, Timisoara 300041, Romania

<sup>2</sup> Department of Neurosciences, "V. Babes" University of Medicine and Pharmacy, Timisoara 300041, Romania; reisz\_daniela@yahoo.com

<sup>3</sup> Department of Gynecology, "V. Babes" University of Medicine and Pharmacy, Timisoara 300041, Romania; dr.petreizabella@yahoo.com

<sup>4</sup> Department of Hematology, "V. Babes" University of Medicine and Pharmacy, Timisoara 300041, Romania; mdioanaionita@yahoo.com

\* Corresponding author: doinageox@gmail.com

Submitted: 9 December 2019, accepted: 15 December 2019, published: 17 December 2019

**Abstract:** A 26 year old woman was admitted to the emergency room 2 weeks after delivery of a healthy baby by cesarean(C) section, presenting right hemiparesis and speech disturbances, preceded by headaches. Clinical examination, biochemical tests, magnetic resonance imaging (MRI) and MRA (magnetic resonance angiogram) confirmed the diagnosis of ischemic stroke due to a cerebral venous thrombosis with secondary hemorrhage transformation. Further coagulation work-ups revealed a possible thrombogenic condition with important protein S deficiency. Many therapeutic challenges have been encountered. Multiple seizures attacks further complicated the whole clinical picture, but a gradually recovery was slowly achieved. By the day of discharge, her neurological status greatly improved. A temporary headache was reported after hospital discharge with alleviation in time.

**Keywords:** stroke; cerebral vein thrombosis; postpartum

**How to cite:** Georgescu, D.; Reisz, D.; Petre, I.; Ionita, I. Ischemic Stroke Secondary to Cerebral Venous Thrombosis: A Case Report. *Cent. Eur. Ann. Clin. Res.* **2019**, 1(1), 7; doi:[10.35995/ceacr1010007](https://doi.org/10.35995/ceacr1010007).

© 2019 Copyright by the authors. Licensed as an open access article using a CC BY 4.0 license.



## Introduction

Thrombosis is a process characterized by formation of a clot, whether arterial or venous, which can produce, depending on its size, a partially or totally blockage of blood flow, resulting in important local consequences. Depending on its location, underlying conditions and associated comorbidities, thrombosis could present a wide range of symptoms and signs [1]. While limb, cardiac or abdominal thrombosis could be relatively easy diagnosed by duplex examination [2], other localizations (brain, thorax) require angio-CT or magnetic resonance angiogram (MRA) examination in order to confirm the diagnosis [3]. Cerebral thrombosis is recognized as an important cause of stroke, but localization of thrombotic process is usually arterial and rarely venous. Cerebral venous thrombosis (CVT) affecting

intracranial veins and sinuses is an uncommon cause of stroke and due to its heterogenic clinical features and lack of specificity is often difficult to diagnose [4,5]. Several general and local conditions could trigger CVT. Some conditions are inherited: deficiency of protein C, S, or antithrombin (AT) III, mutation of factor V Leiden G1691A, prothrombin gene G20210A or FII gene, while others are acquired: lupus anticoagulant, vasculitis, brain cancer, trauma, infections/sepsis or arterio-venous malformations, pregnancy and peri puerperium, hormone use—oral contraceptives, chronic mieloproliferative diseases and paroxysmal nocturnal hemoglobinuria.

Apart from these thrombogenic conditions, platelet mitochondria related respiration metabolism is recently believed to play an important role not only in clot formation and thrombosis but also in developing various diseases [6].

## Case Report

### Diagnosis Approach

A young woman aged of 26, with no past medical or family history, except irritable bowel syndrome (IBS) was admitted at the emergency room 2 weeks after delivery of a healthy baby-boy by cesarean (C) section, presenting right hemiparesis and speech disturbances, preceded by headaches. Stroke was diagnosed and the case was referred to the neurologist for further evaluation and management.

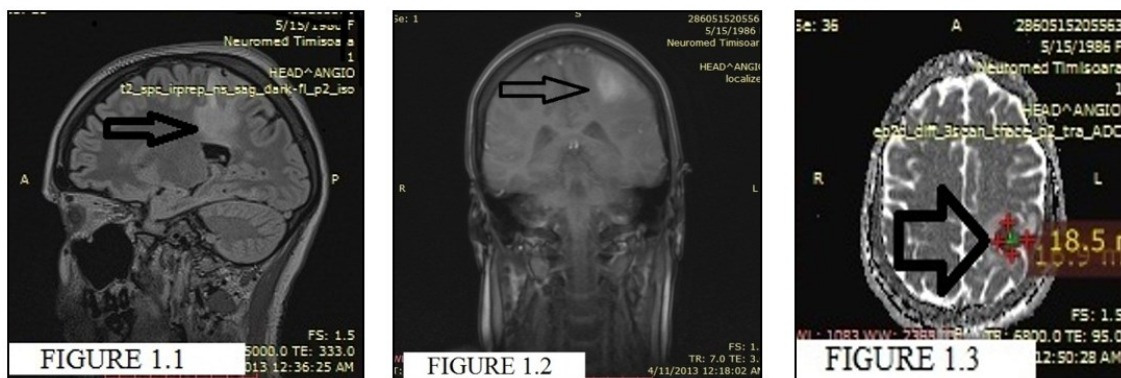
Clinical examination of the patient exhibited no meningeal signs (no neck stiffness), no possibility of maintaining orthostatism, right facial and brachial hemiparesis, dysmetria with hypermetria, hypoesthesia on the right hemicorpus, right central facial palsy, dysarthria—a motor aphasia.

A complete blood count and chemistry panel blood test were performed revealing the following: hemoglobin (Hb) 14.1 g/mL, leukocytes (L) 9570/mm<sup>3</sup>, platelets (PLT) 269.10<sup>3</sup>/mL; erythrocyte sedimentation rate (ESR) 44 mm/h, fasting blood sugar 93 mg%, total cholesterol 299 mg%, high density of lipoproteins (HDL) 32 mg%, low density of lipoproteins (LDL) 177 mg%, triglycerides (TG) 510 mg%, total lipids 1261 mg%, uric acid 7.9 mg%; alanine aminotransferase (ALAT) 30 IU/mL, aspartate aminotransferase (ASAT) 24 IU/mL, creatinekinase (CK) 19 IU/mL, CK-MB 17 IU/mL, creatinine 0.82 mg%, lactic dehydrogenase (LDH) 502 IU/mL, international normalized ratio (INR) = 1.50; fibrinogen 365 mg%, homocysteinemia 9.51 μmol/L, activated partial thromboplastin time (APTT) = 30 s, D-dimer 0.45 μg/mL, thyroid stimulating hormone (TSH) = 2.66 μmol/mL, no pathological aspects of urinalysis: no hematuria, proteinuria or leucocyturia. The first lab panel showed a slightly increased INR, a mixed dyslipidemia and mild hyperuricemia.

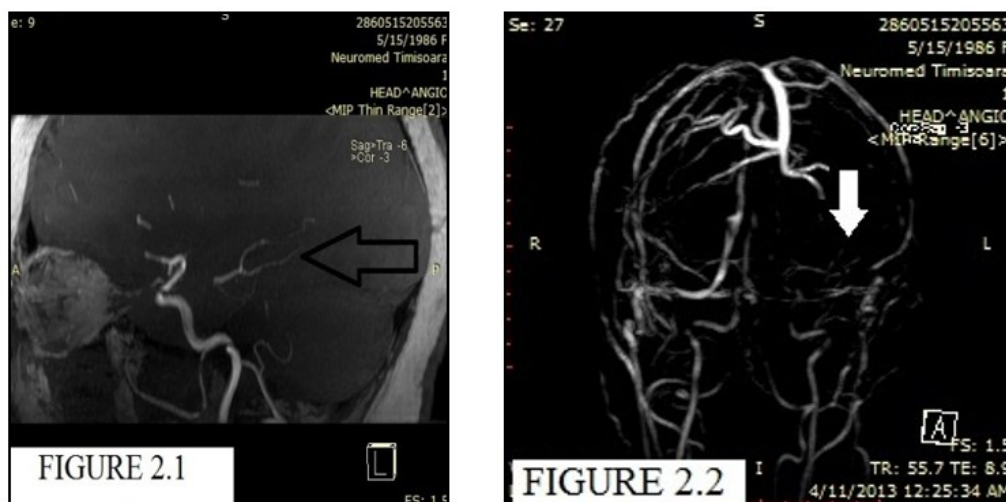
MRI scans showed a cortico-subcortical left parietal infarction with hemorrhagic transformation, and 1.8/1.4/1.6 cm hematoma, perilesional brain edema with slightly compressive effect on ventricular triangle. Many other small, infracentimetric bilateral ischemic lesions (Figure 1) were also observed.

Considering the clinical context of peripartum, the suspicion of cerebral venous thrombosis (CVT) emerged.

A MRA was ordered and performed. As shown in Figure 2, no lesions of the arterial circus of Willis were seen, but subacute obstructive thrombosis of the posterior half of the sagittal sinus and partially obstructive thrombosis of the left transverse sigmoid sinus and internal jugular vein were highlighted. Non obstructive thrombi in the right sigmoid system were also reported.



**Figure 1.** Cerebral MRI: Cortico-subcortical left parietal infarction (arrow) at the post central gyrus (1.1 and 1.2) with hemorrhagic transformation and 1.8/1.4/1.6 cm hematoma (arrow) with perilesional edema (1.3).



**Figure 2.** Cerebral MRA: Subacute obstructive left transverse, sigmoid venous sinus and internal jugular vein thrombosis (black and white arrow): sagittal view (2.1) and coronal view (2.2).

After first set of tests and imaging studies the diagnosis was: left parietal subacute cerebral infarction with hemorrhagic transformation and subacute obstructive left transverse and sigmoid venous sinus thrombosis.

A few interdisciplinary consultations were ordered. The obstetrician confirmed that postpartum had a normal evolution. Ablactation was initiated with bromocriptine 2.5 mg, p.o., b.i.d., for 10 days. The hematologist hypothesized a possible thrombophilia and suggested other coagulation tests. Further coagulation work-ups showed an important protein S deficiency (22.8%) with a normal level of activity of protein C (127.4%) and AT III (121.1%). To verify whether the observed thrombophilia was primary or secondary, additional exams were performed. There was no evidence of collagenosis: no lupus anticoagulant (anti-cardiolipin antibodies IgM and IgG: 14 MPLU/mL and 3.7 GPLU/mL), negative anti-nuclear antibodies and no anti-phospholipidic syndrome (anti-phospholipid antibodies IgM 0.9 MPLU/mL and IgG 3 GPLU/mL) no inflammatory, infectious or malignant conditions were revealed. It was concluded that the patient was probably affected by primary thrombophilia with protein S deficiency.

## Therapeutic Approach

After a lot of debates with pros and cons, anticoagulation therapy was chosen and the patient underwent heparin with low molecular weight (HLMW): nadroparin calcium was subcutaneously administrated at a dose of 3800 IU, b.i.d., for 3 weeks; 2 days before patient discharge, a switch to dabigatran 75 mg, p.o., b.i.d. was made. Diuretics were also administrated: furosemide 40 mg/day, p.o. for 1 week and 20 mg/day, p.o. for other 5 days under ionogram observation, as well as mannitol 500 mL/day, iv administrated for 3 days, in order to control cerebral edema. The antiepileptic lamotrigine was given at 100 mg/day, p.o. as well as sedation with diazepam 10 mg/day, p.o. Prophylactic antibiotics (amoxicillin/clavulanic acid) were given at 1 gr/day, b.i.d, p.o., for 1 week, with progressive recovery.

Evolution with early multiple episodes of local and generalized seizures was managed with antiepileptic drugs (lamotrigine at increasing doses up to 100 mg/day, p.o.). The patient was discharged after 25 days of hospitalization with recommendations of oral treatment with dabigatran 75 mg/day, b.i.d., lamotrigine 100 mg/day, rosuvastatin 20 mg/day, neurological active follow-up and other hematology consultations. The first neurological ambulatory visit, one month after discharge showed a patient in good shape, with no other seizure attacks, however complaining of persistence of a mild headache. The next MRA didn't show any other new thrombotic lesions. Lamotrigine was withdrawn from treatment and the patient continued on previous medication until the next visit. The second ambulatory visit showed mitigated scattered headaches and in fact a full recovered patient.

## Discussions

Venous cerebral infarction, as reported in many previously published studies, is a rare cause of ischemic stroke, representing between 0.5% and 1% of all strokes [7]. Given the complexity of causes and the presenting diversity of ischemic stroke and due to the lack of specificity of symptoms and signs, diagnosis can be sometimes difficult. A very important part of diagnosis rationale is good anatomy knowledge, while symptoms displayed by patients are close related to region of thrombotic event [8]. In this case, headache preceding the stroke in a young woman in postpartum condition was the "key symptom" that raised the suspicion of CVT in the first place. According to many researchers, headache is one of the most frequent presentation symptoms in CVT, occurring in up to 90% of cases, consecutively to increased intracranial pressure [8,9]. It is also well known that pregnancy, C-section and peripartum conditions increase coagulation and favor possible thrombotic events. However, the frequency of CVT in the postpartum period was estimated at 12 cases per 100,000 deliveries, being in fact very low [10].

Age distribution studies showed that there is a bigger incidence of CVT among young people: 78% of cases occurred in patients under age of 50.

Thrombophilias, inflammatory state, dehydration and infections, oral contraceptives use, head trauma should all be investigated and ruled-out when it comes to a case of thrombotic stroke. Unfortunately only some of them are reversible [11,12]. Some authors hypothesized that lumbar puncture could sometimes associate a CVT, suggesting that decrease in cerebral venous blood flow could trigger venous thrombosis. This hypothesis could be theoretically introduced in discussion, since patient got a recently surgical intervention (C section delivery) preceded by epidural anesthesia, but yet we believe that would be rather a speculation than a fact [13]. Studies regarding D-dimer level in CVT reported discordant findings and no D-dimers elevation in subacute thrombosis is sometimes seen. That means that a negative D-Dimer test, as we observed, does not necessary rules out the diagnosis of thrombosis [14].

Thrombosis of the transverse sinus seems to be one of the most frequent localization (41–45%) of cerebral venous thrombosis, as we also observed in this case. The absence of a uniform treatment approach in CVT is an important issue [15]. Hemorrhagic transformation of ischemic infarction is another big challenge to overcome in these cases. Our unanimous opinion was to go for anticoagulation after a thorough evaluation of the risks and benefits, taking into account all the clinical particularities. Generally, if there are no major contraindications to anticoagulation treatment, then anticoagulation therapy should be started and continued as long as it's necessary, which in this case was a long term treatment [16].

The decision of administering steroid therapy should also be considered, taking into account risks and benefits: reducing the vasogenic edema but increasing the coagulability, favoring hyperglycemia and high lactate [17]. In this case, considering cerebral edema and the possibility of triggering other mechanical complications, a short course of steroid therapy came into discussion. Finally, because of the high risk of hypercoagulability we rejected this therapy.

Seizures with repetitive pattern either focally, or generalized were another issue to solve in this case. According to Ameri et al. [18], seizures are quite frequently reported in up to 37% of adults with CVT and the treatment with antiepileptic drugs should be initiated due to the possibility of increased cerebral hypoxic damage.

Persistence of headaches after recovery was reported in patients initially admitted to hospital with isolated increased intracerebral pressure, but frequently of low importance. Long term persistence of headaches after stroke recovery advocates the lumbar puncture to rule out elevated intracranial pressure, which in our patient was not the case: headaches showed a decrease intensity and frequency over the time [19]. On the other hand, IBS patient's history could equally favor several types of associated functional pain conditions, such as: headaches, fibromyalgia, chronic pelvic pain, etc., aspects that should be taken into account and further evaluated [20,21].

Secondary prevention of CVT should also be discussed due to risk of recurrence. The overall rate of recurrent CVT according to the ISCVT is 4.1 per 100 person/years, with male sex and polycythemia/thrombocytosis being the only independent predictors found [22]. In this case long term therapy with newly oral anticoagulation was recommended.

## Conclusion

We have presented a case of a young female patient with multiple concurrent procoagulant conditions (age and gender, puerperium, delivery by C-section, protein S deficiency, probably preexistent), who experienced an ischemic stroke secondary to a thrombotic event at the cerebral vein territory, raising challenges in both diagnostics and management.

**Author Contributions:** Conceptualization, D.G.; Methodology, D.G.; Software, I.P.; Validation, D.G., D.R., I.P. and I.I.; Formal Analysis, D.G.; Investigation, D.G., D.R.; Resources, D.G. and I.P.; Data Curation, D.G.; Writing—Original Draft Preparation, D.G.; Writing—Review & Editing, D.G., I.P. and I.I.; Visualization, I.P.; Supervision, D.G.; Project Administration, D.G.

**Funding:** This research received no external funding.

**Conflicts of Interest:** The authors declare no conflict of interest.

## References

1. Georgescu, D.; Iurciuc, M.; Ionita, I.; Georgescu, L.A.; Muntean, M.; Lascu, A.; Ionita, M.; Lighezan, D. Portal vein Thrombosis and Gut Microbiota: Understanding the Burden. *Revista de Chimie* **2019**, *70*, 2181–2185.



2. Georgescu, D.; Georgescu, L.A.; Muntean, M.; Lighezan, D. Duplex abdominal examination in portal vein obstruction: How much can we rely on? *Ultraschall in der Medizin* **2016**, *37*, SL13\_5. [[CrossRef](#)]
3. Bonneville, F. Imagerie des thromboses veineuses cérébrales. *Journal de Radiologie Diagnostique et Interventionnelle* **2014**, *95*, 1130–1135. [[CrossRef](#)]
4. Flores-Barragan, J.M.; Hernandez-Gonzalez, A.; Gallardo-Alcaniz, M.J.; Del Real-Francia, M.A.; Vaamonde-Gamo, J. Clinical and therapeutic heterogeneity of cerebral venous thrombosis: A description of a series of 20 cases. *Rev. Neurol.* **2009**, *49*, 573–644. [[PubMed](#)]
5. Bentley, J.N.; Figueroa, R.E.; Vender, J.R. From presentation to follow-up: Diagnosis and treatment of cerebral venous thrombosis. *Neurosurg. Focus* **2009**, *27*, E4. [[CrossRef](#)] [[PubMed](#)]
6. Petrus, A.T.; Lighezan, D.L.; Danila, M.D.; Duicu, O.M.; Sturza, A.; Muntean, D.M.; Ionita, I. Assess of platelet respiration as emerging biomarker of disease. *Physiol. Res.* **2019**, *68*, 347–363. [[CrossRef](#)] [[PubMed](#)]
7. Bousser, M.G.; Ferro, J.M. Cerebral venous thrombosis: An update. *Lancet Neurol.* **2007**, *6*, 162–170. [[CrossRef](#)]
8. Wasay, M.; Kojan, S.; Dai, A.I.; Bobustuc, G.; Sheikh, Z. Headache in Cerebral Venous Thrombosis: Incidence, pattern and location in 200 consecutive patients. *J. Headache Pain* **2010**, *11*, 137–139. [[CrossRef](#)] [[PubMed](#)]
9. Ferro, J.M.; Crassard, I.; Coutinho, J.M.; Canhão, P.; Barinagarrementeria, F.; Cucchiara, B. Decompressive surgery in cerebrovenous thrombosis: A multicenter registry and a systematic review of individual patient data. *Stroke* **2011**, *42*, 2825–2831. [[CrossRef](#)]
10. Ruiiz-Sandoval, J.L.; Cantu, C.; Barinagarrementeria, F. Intracerebral hemorrhage in young people: Analysis of risk factors, location, causes, and prognosis. *Stroke* **1999**, *30*, 537–541. [[CrossRef](#)]
11. Stam, J. Cerebral venous and sinus thrombosis: Incidence and causes. *Adv. Neurol.* **2003**, *92*, 225–232.
12. Ferro, J.M. Causes, predictors of death, and antithrombotic treatment in cerebral venous thrombosis. *Clin. Adv. Hematol. Oncol.* **2006**, *4*, 732–733.
13. Canhão, P.; Batista, P.; Falcão, F. Lumbar puncture and dural sinus thrombosis—A causal or casual association? *Cerebrovasc. Dis.* **2005**, *19*, 53–56. [[CrossRef](#)]
14. Kosinski, C.M.; Mull, M.; Schwarz, M.; Koch, B.; Biniek, R.; Schäfer, J.; Milkereit, E.; Willmes, K.; Schiefer, J. Do normal D-dimer levels reliably exclude cerebral sinus thrombosis? *Stroke* **2004**, *35*, 2820–2825. [[CrossRef](#)]
15. Stam, J. Thrombosis of the cerebral veins and sinuses. *N. Engl. J. Med.* **2005**, *352*, 1791–1798. [[CrossRef](#)]
16. Einhaupl, K.M.; Villringer, A.; Meister, W.; Mehraein, S.; Garner, C.; Pellkofer, M.; Haberl, R.L.; Pfister, H.W.; Schmiedek, P. Heparin treatment in sinus venous thrombosis. *Lancet* **1991**, *338*, 597–600. [[CrossRef](#)]
17. Canhao, P.; Cortesão, A.; Cabral, M.; Ferro, J.M.; Stam, J.; Bousser, M.G.; Barinagarrementeria, F.; ISCVT Investigators. Are steroids useful to treat cerebral venous thrombosis? *Stroke* **2008**, *39*, 105–110. [[CrossRef](#)]
18. Ameri, A.; Bousser, M.G. Cerebral venous thrombosis. *Neurol. Clin.* **1992**, *10*, 87–111. [[CrossRef](#)]
19. Cumurciuc, R.; Crassard, I.; Sarov, M.; Valade, D.; Bousser, M.G. Headache as the only neurological sign of cerebral venous thrombosis: A series of 17 cases. *J. Neurol. Neurosurg. Psychiatry* **2005**, *76*, 1084–1087. [[CrossRef](#)]

20. Georgescu, D.; Reisz, D.; Gurban, C.V.; Georgescu, L.A.; Ionita, I.; Ancusa, O.E.; Lighezan, D. Migraine in young females with irritable bowel syndrome: Still a challenge. *Neuropsychiatr. Dis. Treat.* **2018**, *14*, 21–28. [[CrossRef](#)]
21. Georgescu, D.; Iurciuc, M.S.; Petre, I.; Georgescu, L.A.; Szasz, F.; Ionita, I.; Ancusa, O.E.; Ionita, M.; Lighezan, D. Chronic Pelvic Pain and Irritable Bowel Syndrome: Is Subclinical Inflammation Bridging the Gap? *Revista de Chimie* **2019**, *70*, 3634–3637.
22. Ferro, J.M.; Canhao, P.; Stam, J.; Bousser, M.G.; Barinagarrementeria, F.; ISCVT Investigators. Prognosis of cerebral vein and dural sinus thrombosis: Results of the International Study on Cerebral Vein and Dural Sinus Thrombosis. *Stroke* **2004**, *35*, 664–670. [[CrossRef](#)]